EGAS MONIZ SCHOOL of HEALTH & SCIENCE

EGAS MONIZ SCIENCE DAYS



FRACTURED IRRIGATION NEEDLE DETECTED ON THE MASTER CONE RADIOGRAPH : A CASE REPORT

INTRODUCTION

Although irrigation needle fracture is rare in endodontics, instrument separation is a relatively common procedural complication (1.83–8.2%), with molars presenting a significantly higher risk than premolars [1,2].

CLINICAL CASE HISTORY

A 46-year-old patient presented for root canal obturation of tooth 37, diagnosed with initiated therapy and a chronic periapical abscess.

Root canal instrumentation had been previously performed by other students, with **no complications reported**.

CLINICAL CASE REPORT

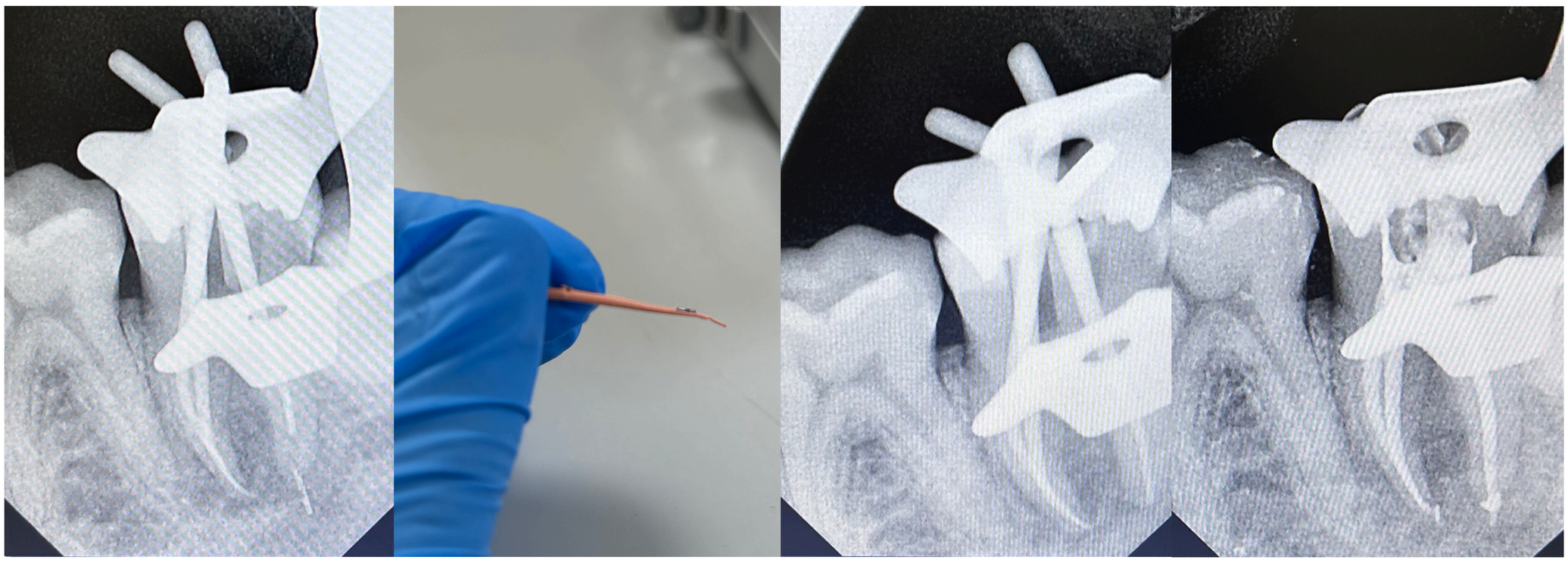

Initial master cone radiograph revealing a radiopaque image suggestive of an intracanal foreign body

Fragment retrieved inadvertently during master cone removal and identified as the tip of a side-vented irrigation needle

Second master cone radiograph confirming adequate cone position

Final postoperative radiograph showing the completed root canal obturation

DISCUSSION & CONCLUSION

Prevention strategies

- Obtain radiographs before intervening in an existing case to identify potential complications and avoid exacerbating them. In our case, cone insertion during the master cone fitting may have pushed the fragment further apically.
- Ensure passive needle insertion without binding, 1–2 mm short of working length, with gentle irrigation and continuous needle movement [3,4].

This case highlights that procedural complications may be present before treatment and can potentially be aggravated by subsequent clinical procedures. Careful radiographic assessment, combined with a cautious approach to instrumentation and irrigation, is therefore essential to minimise further complications and ensure patient safety.

REFERENCES

1. Alamoudi RA, et al. Assessment of incidence, management and contributory factors of root canal instrument separation. Niger J Clin Pract. 2024;27:16–21.
2. Iqbal MK, et al. Incidence of root canal instrument separation: a PennEndo database study. J Endod. 2006;32:1048–52.
3. Suter B, et al. Probability of removing fractured instruments from root canals. Int Endod J. 2005;38:112–23.
4. Nevares G, et al. Success rates for removing or bypassing fractured instruments. J Endod. 2012;38:442–4.

Elia Collay, Aluna do Mestrado Integrado em Medicina Dentaria
Maria Helena Duarte, Médica Dentista em Formação Voluntária no Departamento de Medicina Dentária Conservadora (Endodontia)